

CANCER INDUCED CHANGES IN PROSTATE TISSUE REVEALED BY NONLINEAR MICROSCOPY

Austėja Bareikytė¹, Viktoras Mažeika^{1,2}, Mykolas Mačiulis¹, Margarita Žvirblė^{2,3}, Darius Dasevičius⁴, Virginijus Barzda^{1,5}

¹Laser Research Centre, Faculty of Physics, Vilnius University, Saulėtekio al. 9, Vilnius, Lithuania

²Institute of Biosciences, Life Sciences Center, Vilnius University, Saulėtekio al. 7, Vilnius, Lithuania

³Laboratory of Immunology, National Cancer Institute, Santariškių g. 1, Vilnius, Lithuania

⁴Center of Pathology, Vilnius University Hospital Santaros Clinics, P. Baublio g. 5, Vilnius, Lithuania

⁵Department of Chemical and Physical Sciences, Department of Physics, University of Toronto, 3359 Mississauga Road, Mississauga, ON, Canada
austejabar@gmail.com

Prostate cancer, second most frequently occurring oncological disease among male globally, tend to remain undetected for years due to the lack of symptoms in early stages [1]. Traditional diagnostic methods, including prostate-specific antigen (PSA) testing, and biopsy, have limitations in accuracy resulting in false diagnosis [2]. Nonlinear imaging techniques, such as second harmonic generation (SHG), third harmonic generation (THG) and multiphoton emission fluorescence (MPEF), offer deeper tissue visualization and have shown potential in examining lung, breast and ovaries cancerous tissues [3], [4]. The aim of this work is to use imaging techniques that involve nonlinear processes, polarization and gray level co-occurring matrix (GLCM) based texture analysis to get a deeper structural understanding of the histological prostate cancer samples.

In this experiment, SHG imaging was used to analyse the arrangement of collagen fibers in the tissue. Double Stokes-Mueller polarimetry (DSMP) measurements revealed ultrastructural changes in the extracellular matrix of the prostate tissue in case of fibrosis. In other cases collagen structure of cancerous tissue did not seem to differ from the normal prostatic tissue. Texture analysis and Kruskal-Wallis statistical test for THG images showed significant differences between cancerous and normal tissues, highlighting its potential in cancer diagnosis.

Overall, all of the three contrast mechanisms (SHG, THG and MPEF) can be described as complimentary, each of them providing different information and offering a promising approach for diagnosis and understanding of prostate cancer.

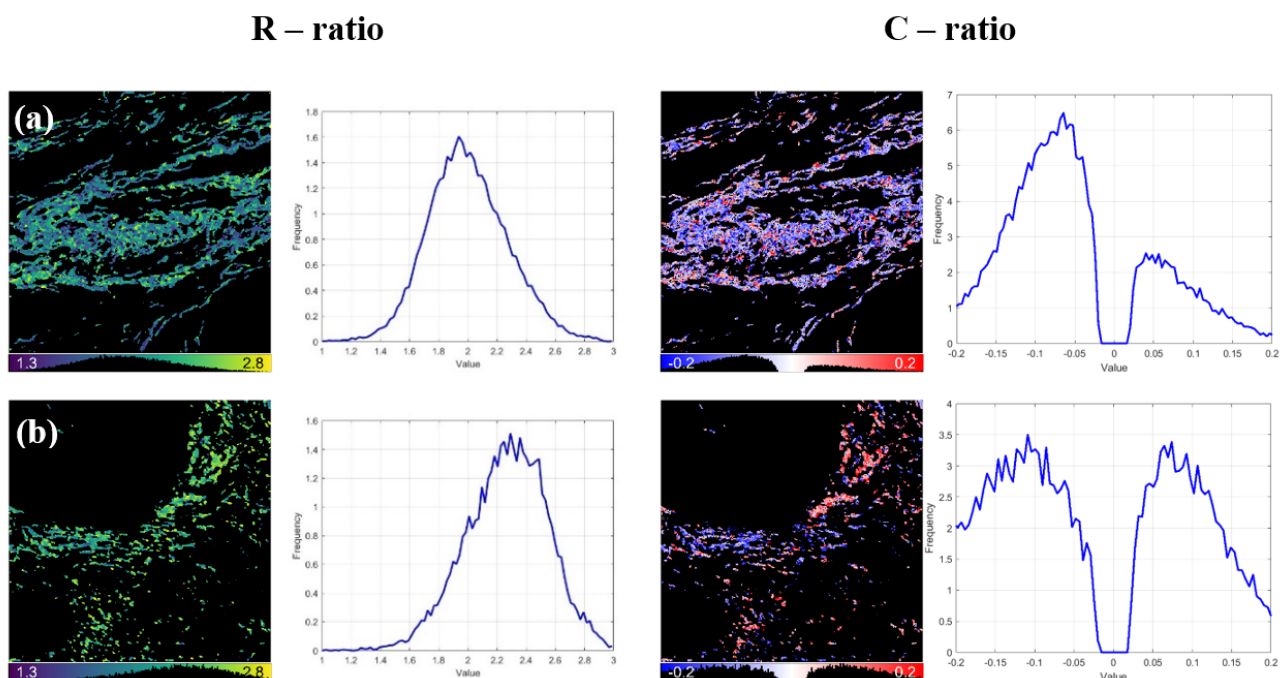


Fig. 1. DSMP measurements of sample No. 1 of (a) normal and (b) tumor tissues, R and C ratio distribution maps and their histograms.

[1] P. Rawla, 'Epidemiology of Prostate Cancer', *World J Oncol*, vol. 10, no. 2, pp. 63–89, Apr. 2019

[2] 'Apie prostatos vėžį', Vilniaus universiteto Onkologijos institutas, 2006

[3] L. Wang, B. Lu, M. He, Y. Wang, Z. Wang, and L. Du, 'Prostate Cancer Incidence and Mortality: Global Status and Temporal Trends in 89 Countries From 2000 to 2019', *Front Public Health*, vol. 10, p. 811044, Feb. 2022

[4] A. Golaraei, 'Polarimetric Second-Harmonic Generation Microscopy for Histopathology', Thesis, 2018